

A Prothrombotic Thrombocytopenic Disorder Resembling Heparin-Induced Thrombocytopenia Following Coronavirus-19 Vaccination

Andreas Greinacher (✉ andreas.greinacher@med.uni-greifswald.de)

Universitätsmedizin Greifswald

Thomas Thiele

Universitätsmedizin Greifswald

Theodore E. Warkentin

McMaster University

Karin Weisser

Paul Ehrlich Institut

Paul Kyrle

Medical University of Vienna

Sabine Eichinger

Medical University of Vienna

Research Article

Keywords: SARS-CoV-2; vaccine, thrombosis, cerebral vein thrombosis

DOI: <https://doi.org/10.21203/rs.3.rs-362354/v1>

License: © ⓘ This work is licensed under a Creative Commons Attribution 4.0 International License. [Read Full License](#)

Abstract

Background. Vaccines are important for managing the COVID-19 pandemic caused by SARS-CoV-2. However, following widespread vaccination using a recombinant adenoviral vector encoding the spike protein antigen of SARS-CoV-2 (AZD1222, AstraZeneca), reports have emerged of some vaccine recipients developing unusual thrombotic events and thrombocytopenia. We investigated whether such patients could have a prothrombotic disorder caused by platelet-activating antibodies directed against platelet factor 4 (PF4), as is known to be caused by heparin and sometimes other environmental triggers.

Methods. We summarized the clinical and laboratory features of 9 patients in Germany and Austria who developed thrombosis and thrombocytopenia events following AZD1222 vaccination. Serum from four patients was used to test for anti-PF4/heparin antibodies, both by immunoassay and by platelet activation assays performed in the presence of heparin, PF4, or both.

Results. The 9 patients (8 female; median age, 36 [range, 22–49]) presented with thrombosis beginning 4 to 16 days post-vaccination: 7 patients had cerebral venous thrombosis (CVT), 1 had pulmonary embolism, and 1 had splanchnic vein thrombosis and CVT; 4 patients died. None had received heparin prior to symptom onset. All four patients tested strongly positive for anti-PF4/heparin antibodies by immunoassay; all 4 patients tested strongly positive in the platelet activation assay in the presence of PF4 independently of heparin. Platelet activation was inhibited by high concentrations of heparin, Fc receptor-blocking monoclonal antibody, and intravenous immunoglobulin.

Conclusions. The AZD1222 vaccine is associated with development of a prothrombotic disorder that clinically resembles heparin-induced thrombocytopenia but which shows a different serological profile.

Introduction

Vaccines against severe acute respiratory syndrome coronavirus-2 (SARS-CoV-2) are the most important countermeasure to fight the COVID-19 pandemic. Vaccines induce a robust immune response including T-cell and B-cell responses.

Between December 2020 and March 2021, the European Medical Agency approved four vaccines based on randomised, blinded, controlled trials: Comirnaty (Pfizer/BioNTech), a nucleoside modified mRNA COVID-19 vaccine; an mRNA-based vaccine encapsulated in lipid nanoparticle (Moderna); a recombinant adenoviral (ChAdOx1) vector encoding the spike protein antigen of SARS-CoV-2, AZD1222 (AstraZeneca); and a recombinant adenovirus type 26 vector encoding SARS-CoV-2 spike glycoprotein COVID-19 Vaccine (Janssen). By March 19, 2021, approximately 55 million vaccine doses have been administered in the European Union (<https://ourworldindata.org/covid-vaccinations>, last accessed March 19, 2021). Beginning in late February 2021 several cases of unusual thrombotic events in combination with thrombocytopenia were observed in patients after COVID-19 vaccination.

Index case

A previously healthy 49-year-old nurse received her first dose of AZD1222 vaccine (AstraZeneca) in mid-February 2021 (day 0). She had minor complaints (fatigue, myalgia, headache) over the next few days. Beginning on day 5, she developed chills, fever, nausea and epigastric discomfort, and was admitted to a local hospital on day 10.

Results of the laboratory work-up are shown in Table 1. The platelet count was 18 per cubic millimeter, and d-Dimer was 35.2 mg/l (reference range, < 0.5). All other blood tests except gamma glutamyl transferase and C-reactive protein were normal. SARS-CoV-2 reverse-transcriptase polymerase-chain-reaction assay of a nasopharyngeal swab was negative.

Table 1
Laboratory characteristics of a patient with venous and arterial thrombosis at unusual sites (case 1)

	Day 10 8:00	Day 10 20:00	Day 11 8:00	Day 11 20:00
Hemoglobin (g/dl)	12.3	11.3	10.9	9.1
Platelet count (per cubic millimeter)	18	37	25	13
Leukocytes (per cubic millimeter)	6.6	7.1	10.9	15.5
Activated partial thromboplastin time (seconds), normal < 35	34	41.6	37.9	32.3
Prothrombin time (International Normalized Ratio)	1.4	1.3	1.2	1.3
Thrombin time (seconds), normal < 21	n.a.	25.7	n.a.	23.7
Fibrinogen (mg/dl), normal range 200–400	n.a.	101	126	78
D-Dimer (µg/ml), normal < 0.5	35	142	n.a.	n.a.
Aspartate-Aminotransferase (U/l), normal range < 35	33	88	160	98
Alanine-Aminotransferase (U/l), normal < 35	46	94	167	155
Gamma glutamyl transferase (U/l), normal < 40	141	110	103	78
Lactate dehydrogenase (U/l), normal < 250	n.a.	337	n.a.	344
C-reactive protein (mg/dl), normal < 0.5	8.8	7.6	8.7	6.8
Lactate (mmol/l), normal < 1.6	0.9	n.a.	1.7	3.6
n.a. not assessed				

Computed tomography (CT) imaging showed portal vein thrombosis and peripheral pulmonary emboli. The patient received a platelet concentrate and was transferred to a tertiary hospital. Upon arrival, she complained of epigastric discomfort and nausea, but was otherwise in good condition (blood pressure 125/88, heart rate 65 beats per minute, temperature 36.5° C). Physical examination was unremarkable except for moderate epigastric pain on palpation. She received intravenous antibiotics, analgesia, and one 4,000 unit dose of low-molecular-weight heparin (enoxaparin), given subcutaneously.

The following day, platelet count and fibrinogen levels remained low and d-Dimer and transaminase levels increased (Table 1). Abdominal pain worsened and repeat CT imaging showed progression of portal vein thrombosis to include the splenic and upper mesenteric veins; in addition, small thrombi were visualized in the infrarenal aorta and both iliac arteries. Low-dose intravenous unfractionated heparin (500 IU/h) was begun but stopped shortly thereafter because of sudden onset of tachycardia and concern for gastrointestinal bleeding. The lactate was 3.7 mmol/l, and she was transferred to the intensive care unit. Repeat CT imaging revealed diffuse gastrointestinal bleeding with reduced perfusion of intestinal wall and pancreas involved by splanchnic vein thrombosis, and ascites. She received red blood cell and platelet transfusions, prothrombin complex concentrates, and recombinant factor VIIa, but died on day 11.

Case series

By March 15th, 2021, an additional eight patients were identified who developed one or more thrombotic complications beginning four to 16 days following vaccination with AZD1222. Characteristics of all 9 patients are presented in Table 2. Thrombotic events included pulmonary embolism (n = 2), cerebral vein thrombosis (n = 7), splanchnic vein thrombosis (n = 1), and arterial thrombosis (n = 1); some patients had more than 1 thrombotic event. Female predominance was observed (8 of 9 patients, including 7 of 8 patients who had CVT). All patients presented with concomitant thrombocytopenia (median platelet count nadir, 29 per cubic millimeter; range, 9 to 100). Two patients had pre-existing autoimmune disease (1 patient, demyelinating disease; 1 patient, antiphospholipid antibodies), and two patients had an underlying coagulation disorder (1

patient, von Willebrand disease; 1 patient, “unspecified coagulation disorder”). None of the patients had received heparin before onset of symptoms or diagnosis of thrombosis. Given the striking clinical resemblance to heparin-induced thrombocytopenia, a prothrombotic thrombocytopenic disorder triggered by heparin and certain other anions, four of the nine patients had sera referred for investigations of platelet-activating antibodies directed against PF4/heparin (Table 2).

Table 2

Summary of patients presenting with prothrombotic thrombocytopenia after Coronavirus 19 vaccination in Austria (AT) and Germany (GER) February -March 2021

Case	1	2	3	4	5	6	7	8	9
Sex	female	female	female	female	female	female	female	female	male
Age, years	49	35	48	35	43	22	36	46	24
Platelet count nadir (per cubic millimeter)	13	100	31	9	23	75	29	60	11
Site of thrombosis	Splanchnic vein thrombosis, aortic thrombosis, CVT	PE	CVT	CVT	CVT	CVT	CVT	CVT	CVT
Onset of symptom after vaccination, days	5	10	8	4	13	7	8	14	16
Associated autoimmune disease	no	no	no	yes	yes	no	no	no	no
Outcome	fatal	recovering	fatal	fatal	recovering	recovering	recovering	in-hospital	fatal
CVT - cerebral vein thrombosis PE - pulmonary embolism									

Material And Methods

We purified platelets from ACD-A anticoagulated whole blood from healthy volunteers (none were taking antiplatelet drugs or had been vaccinated in the previous 10 days). We prepared platelets as described^{1,2}. In a subset of experiments platelets were preincubated in buffer with the AZD1222 vaccine (diluted 1:2000) and washed before use. Washed platelets (75 μ L) were incubated with either buffer, the low-molecular-weight heparin, reviparin (Abbott, Mannheim, Germany), or platelet factor 4 (PF4) (Chromatec, Greifswald, Germany) in the presence and absence of the Fc γ 1 receptor-blocking antibody, IV.3. In some experiments, 100 IU unfractionated heparin were added to inhibit PF4 dependent reactions; or 2 μ L of the AZD1222 vaccine were added per well. All four sera were co-incubated with PF4 and platelets in the presence of intravenous immunoglobulin (IVIG) at a concentration of 10 mg/mL.

To measure direct antibody binding a PF4/heparin EIA was performed, and antibody binding was measured by a secondary antihuman IgG antibody as described.³

Results

All four patients showed strong reactivity in the PF4/heparin enzyme-immunoassay with optical densities greater than 3.00 units (reference value, < 0.50), all reactivities were inhibited to optical density less than 0.50 units by addition of 100 IU heparin.

All four patient sera activated platelets strongly, either in the presence of 10 µg/mL PF4 (3 of 4 sera) or in the presence of AZD1222 vaccine (1 serum); all reactions were blocked by the monoclonal antibody IV.3 and IVIG 10 mg/mL, demonstrating that platelet activation had occurred through platelet Fcγ receptors (Fig. 1). One serum showed also platelet activation in the presence of heparin. Normal sera showed no platelet activation. None of 20 sera from control individuals who were vaccinated by AZD1222 vaccine caused platelet activation.

Discussion

The clinical picture of patients with moderate to severe thrombocytopenia and thrombotic complications at unusual sites beginning approximately one week after vaccination against SARS-CoV-2 by AZD1222 suggests a disorder clinically resembling heparin-induced thrombocytopenia, a well-recognized prothrombotic disorder caused by platelet-activating antibodies that recognize multimolecular complexes between cationic PF4 and anionic heparin⁴. In recent years, it has been recognized that triggers other than heparin can rarely cause a disorder that strongly resembles heparin-induced thrombocytopenia on both clinical and serological grounds, including certain polyanionic drugs (e.g., pentosan polysulfate⁵, antiangiogenic agent PI-88⁶, hypersulfated chondroitin sulfate⁶, infections (viral, bacterial)⁷, or knee replacement surgery^{8,9}). Indeed, these various scenarios in which an apparent non-heparin trigger has been invoked have been called “spontaneous” heparin-induced thrombocytopenia syndrome^{10,11}. Serological studies using sera from four patients who developed thrombocytopenia and thrombosis (three of them at unusual sites) following vaccination showed strong reactivity in anti-PF4/heparin enzyme-immunoassay, and also showed strong positive testing for platelet-activating antibodies. However, in contrast to patients with typical heparin-induced thrombocytopenia, the laboratory conditions that results in patient serum-induced platelet activation differed. Notably, patient serum strongly activated platelets when PF4, rather than heparin, was added to a washed platelet assay. A similar phenomenon has been observed with some sera from patients who have typical heparin-induced thrombocytopenia¹². It appears that the platelet-activating antibodies induced by vaccination bind to non-complexed PF4 alone, also noted in some sera from patients with heparin-induced thrombocytopenia¹². Whether these antibodies are autoantibodies against PF4 induced by the strong inflammatory stimulus of vaccination or if the vaccine itself triggers the formation of platelet activating antibodies cannot be distinguished by this study. Enhanced reactivity of the sera in vitro in the presence of AZD1222 could be explained by direct binding of the virus to platelets. Adenovirus binds to platelets and can cause platelet preactivation.

There are several important clinical implications of our findings. First, clinicians should be aware that onset of (venous or arterial) thrombosis particularly at unusual sites such as in the brain or abdomen and thrombocytopenia beginning approximately 5 to 14 days after vaccination can represent a rare adverse effect of preceding COVID-19 vaccination. To date, this has only been reported with the AZD1222 vaccine. Second, enzyme-immunoassays for heparin-induced thrombocytopenia are widely available and based on our observations can be used to investigate for potential post-vaccination anti-PF4 antibody associated thrombocytopenia/thrombosis, especially as a strong-positive immunoassay result obtained in a patient who has not been recently exposed to heparin would be a striking abnormality. However, a positive PF4/heparin¹² antigen test by no means confirms the presence of potentially pathogenic vaccine-induced antibodies, especially if the assay is moderate or weak positive, and thus referral to a laboratory that performs platelet-activation assays should be performed. Without clear clinical symptoms of new thrombosis and/or thrombocytopenia patients should not be tested or treated. Third, although this syndrome differs from typical heparin-induced thrombocytopenia, at least one patient showed strong platelet activation in the presence of heparin. In the absence of data indicating safety and efficacy of heparin in treating these patients¹³, we would recommend therapy with non-heparin anticoagulants, such as those direct oral anticoagulants (rivaroxaban, apixaban) which are licensed without requirement for initial heparin therapy. Indeed, direct oral anticoagulants are widely used for treatment of thrombosis in general and have also been recommended for treatment of heparin-induced thrombocytopenia. And fourth, our in vitro studies of inhibition of the platelet-activating properties by high-dose immunoglobulin, together with the recent observations indicating efficacy of high-dose intravenous immunoglobulin for treating severe heparin-induced thrombocytopenia—including so-called “autoimmune heparin-induced thrombocytopenia” in which patients have de novo or ongoing thrombocytopenia in the absence of heparin—suggests that this can be an important treatment adjunct in a patient who develops life-threatening thrombotic

event such as cerebral vein sinus thrombosis post-vaccination^{9,14,15}. Finally we suggest to name this entity vaccine induced prothrombotic immune thrombocytopenia (VIPIT) to avoid confusion with heparin-induced thrombocytopenia (HIT).

Declarations

Ethics

The study has been approved by the ethics board of the Universitätsmedizin Greifswald. Consent has been obtained to publish the case report.

Conflicts of interest:

Dr. Greinacher reports grants and non-financial support from Aspen, Boehringer Ingelheim, MSD, Bristol Myers Squibb (BMS), Paringenix, Bayer Healthcare, Gore Inc., Rovi, Sagent, Biomarin/Prosensa, personal fees from Aspen, Boehringer Ingelheim, MSD, Macopharma, BMS, Chromatec, Instrumentation Laboratory, non-financial support from Boehringer Ingelheim, Portola, Ergomed, GTH e.V. outside the submitted work.

Dr. Thiele reports grants from Deutsche Forschungsgemeinschaft, during the conduct of the study; personal fees and other from Bristol Myers Squibb, personal fees and other from Pfizer, personal fees from Bayer, personal fees and other from Chugai Pharma, other from Novo Nordisk, personal fees from Novartis, other from Daichii Sankyo, outside the submitted work.

Dr. Warkentin reports personal fees from Aspen Global, Ergomed, Instrumentation Laboratory, and Octapharma, all of which are outside of the submitted work.

Dr. Weisser has nothing to disclose.

Dr. Kyrle reports personal fees from Takeda and Novo Nordisk, all of which are outside of the submitted work

Dr. Eichinger reports personal fees from Bayer, Bristol Myers Squibb, Daichii Sankyo, and Pfizer, all of which are outside of the submitted work.

Author contributions:

AG, TT and TEW developed the concept of the mechanism; KW collected all reported cases and organized sample transfer; PK and SE identified and treated the index patient and suspected a HIT like syndrome

Acknowledgements

We acknowledge all the colleagues contributing behind the scenes to this study to refer patient sera to Greifswald. Especially Dr Michael Hirschl, Landesklinikum Zwettl, Austria, Dr Keller-Stanislawski, Dr Mentzer, Prof Cichutek, Paul-Ehrlich Institut, Dreieich, Prof Dr Bänzner, Prof Dr Wolf, Prof Dr Henkes, Klinikum Stuttgart; Prof Dr Bone, Dr Alfes, Dr Atzpodien Klinikum-Vest, Recklinghausen.

The technologists Ulrike Strobel, Carmen Freyer, Katrin Stein, Ines Warnig, Ricarda Raschke, Transfusion Medicine Greifswald

The study has been funded by the Deutsche Forschungsgemeinschaft (DFG, German Research Foundation) – Projektnummer 374031971 – TRR 240“.

References

1. Eichler P, Budde U, Haas S, et al. First workshop for detection of heparin-induced antibodies: validation of the heparin-induced platelet-activation test (HIPA) in comparison with a PF4/heparin ELISA. *Thromb Haemost* 1999;81(4):625–9.
2. Eekels JJM, Althaus K, Bakchoul T, et al. An international external quality assessment for laboratory diagnosis of heparin-induced thrombocytopenia. *J Thromb Haemost* 2019;17(3):525–531. DOI: 10.1111/jth.14383.
3. Juhl D, Eichler P, Lubenow N, Strobel U, Wessel A, Greinacher A. Incidence and clinical significance of anti-PF4/heparin antibodies of the IgG, IgM, and IgA class in 755 consecutive patient samples referred for diagnostic testing for heparin-induced thrombocytopenia. *Eur J Haematol* 2006;76(5):420–6. DOI: 10.1111/j.1600-0609.2005.00621.x.
4. Greinacher A. CLINICAL PRACTICE. Heparin-Induced Thrombocytopenia. *N Engl J Med* 2015;373(3):252–61. DOI: 10.1056/NEJMcp1411910.
5. Tardy-Poncet B, Tardy B, Grelac F, et al. Pentosan polysulfate-induced thrombocytopenia and thrombosis. *Am J Hematol* 1994;45(3):252–7. DOI: 10.1002/ajh.2830450312.
6. Rosenthal MA, Rischin D, McArthur G, et al. Treatment with the novel anti-angiogenic agent PI-88 is associated with immune-mediated thrombocytopenia. *Ann Oncol* 2002;13(5):770–6. DOI: 10.1093/annonc/mdf117.
7. Warkentin TE, Makris M, Jay RM, Kelton JG. A spontaneous prothrombotic disorder resembling heparin-induced thrombocytopenia. *Am J Med* 2008;121(7):632–6. DOI: 10.1016/j.amjmed.2008.03.012.
8. Jay RM, Warkentin TE. Fatal heparin-induced thrombocytopenia (HIT) during warfarin thromboprophylaxis following orthopedic surgery: another example of 'spontaneous' HIT? *J Thromb Haemost* 2008;6(9):1598–600. DOI: 10.1111/j.1538-7836.2008.03040.x.
9. Hwang SR, Wang Y, Weil EL, Padmanabhan A, Warkentin TE, Pruthi RK. Cerebral venous sinus thrombosis associated with spontaneous heparin-induced thrombocytopenia syndrome after total knee arthroplasty. *Platelets* 2020:1–5. DOI: 10.1080/09537104.2020.1828574.
10. Greinacher A, Selleng K, Warkentin TE. Autoimmune heparin-induced thrombocytopenia. *J Thromb Haemost* 2017;15(11):2099–2114. DOI: 10.1111/jth.13813.
11. Warkentin TE, Basciano PA, Knopman J, Bernstein RA. Spontaneous heparin-induced thrombocytopenia syndrome: 2 new cases and a proposal for defining this disorder. *Blood* 2014;123(23):3651–4. DOI: 10.1182/blood-2014-01-549741.
12. Warkentin TE, Nazy I, Sheppard JI, Smith JW, Kelton JG, Arnold DM. Serotonin-release assay-negative heparin-induced thrombocytopenia. *Am J Hematol* 2020;95(1):38–47. DOI: 10.1002/ajh.25660.
13. Cuker A, Arepally GM, Chong BH, et al. American Society of Hematology 2018 guidelines for management of venous thromboembolism: heparin-induced thrombocytopenia. *Blood Adv* 2018;2(22):3360–3392. DOI: 10.1182/bloodadvances.2018024489.
14. Mohanty E, Nazir S, Sheppard JI, Forman DA, Warkentin TE. High-dose intravenous immunoglobulin to treat spontaneous heparin-induced thrombocytopenia syndrome. *J Thromb Haemost* 2019;17(5):841–844. DOI: 10.1111/jth.14411.
15. Warkentin TE. High-dose intravenous immunoglobulin for the treatment and prevention of heparin-induced thrombocytopenia: a review. *Expert Rev Hematol* 2019;12(8):685–698. DOI: 10.1080/17474086.2019.1636645.

Figures

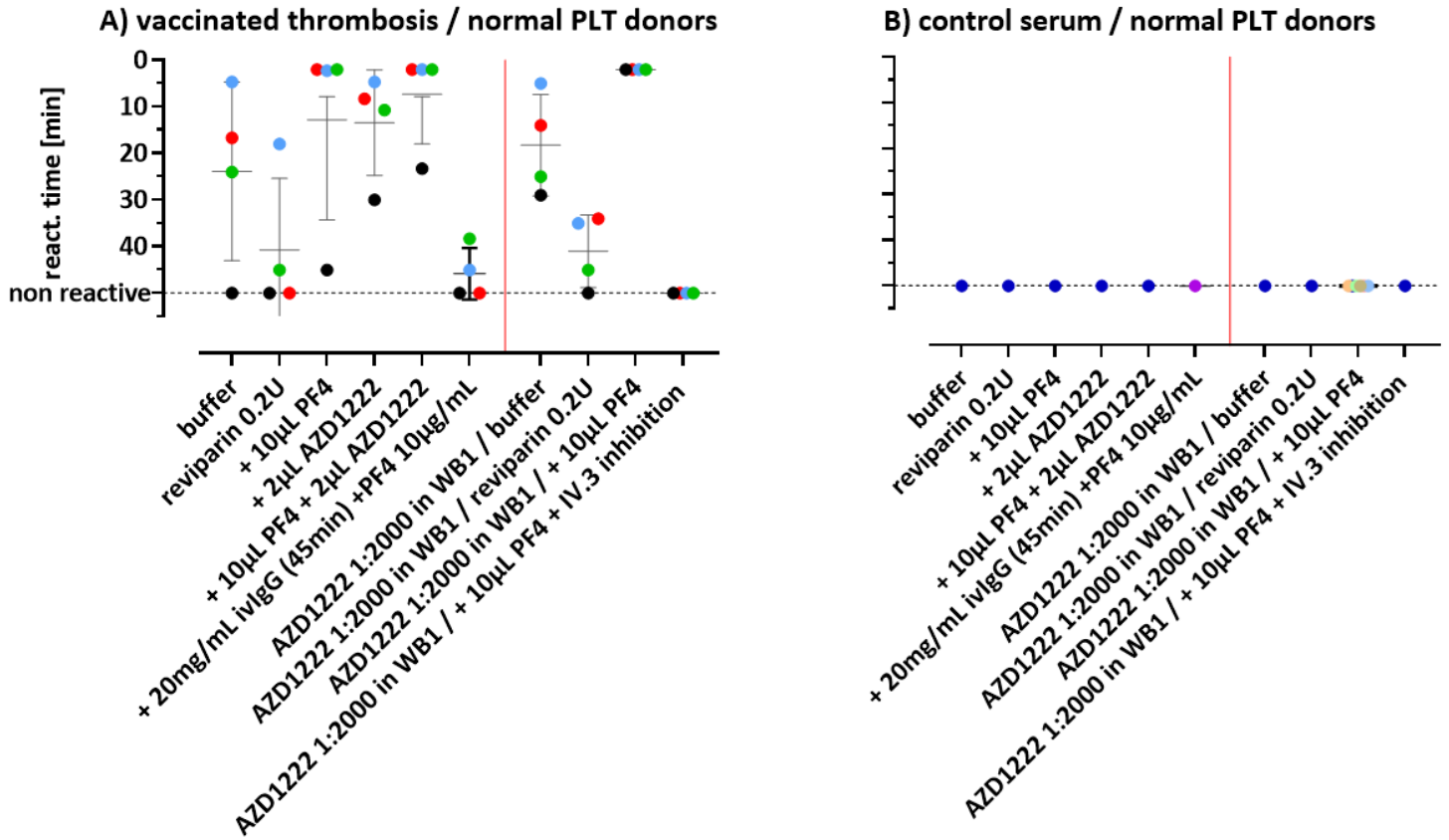


Figure 1

HIPA reaction times (min) as mean of n=3 per datapoint with normal platelet donors. Three of four sera reacted strongly in the presence of PF4 10 µg/mL. Reactivity was enhanced when platelets were coincubated with the vaccine and patient sera, or preincubated with the vaccine and washed before incubation with sera. PF4 = platelet factor 4; AZD1222 = vaccine; WB1 = washing buffer 1; IV.3 = monoclonal antibody inhibiting FcγRIIa